

CASE REPORT

Congenital or Acquired? A Case Report of Extensive Congenital Cholesteatoma

Roslenda AR, Asma A, Iqbal FRW, Jeevanan J

Department of Otorhinolaryngology Head & Neck Surgery, Faculty of Medicine, Universiti Kebangsaan Malaysia, Kuala Lumpur

ABSTRAK

Kolesteatoma kongenital merupakan satu penyakit yang amat jarang ditemui. Ia dikenali sebagai jisim berwarna putih mutiara di sebalik gegendang telinga yang utuh dan normal yang terdapat pada individu yang tidak pernah menjalani sebarang pembedahan telinga. Kes ini melaporkan kanak-kanak lelaki, berumur 6 tahun dengan ketidakselesaan pada telinga kiri selama setahun, diikuti dengan penerarahan sejak dua bulan sebelum mendapat rawatan. Pemeriksaan telinga menunjukkan gegendang telinga kirinya berlubang di bahagian atik. Pemeriksaan radiologi mendapati kanak-kanak ini menghadapi kolesteatoma peringkat akhir yang memenuhi ruang mastoid, mesotimpanum, dan epitympanum, merosakkan semua osikel termasuk plat kaki stapes. Mastoidektomi radikal telah dijalankan. Di sini, klasifikasi rawatan dan teori patogenesis kolesteatoma congenital dibincangkan.

Kata kunci: Kolesteatoma, kepekakan, hilang pendengaran, timpanoplasti, osikel.

ABSTRACT

Congenital cholesteatoma (CC) is rare clinical condition and It is known as a pearly white mass medial to an intact tympanic membrane. In this case report, we describe a 6-year-old boy who presented with a one year history of left ear discomfort, reduced hearing, followed by ear discharge two months prior to admission. Otoscopic examination revealed a large attic perforation. Radiological investigation showed extensive cholesteatoma in the mastoid, mesotympanum and epitympanum with destruction of the ossicles including the stapes footplate. He underwent radical mastoidectomy in view of extensive cholesteatoma with tympanoplasty type V. In this case report, the classification, treatment and theories related to CC are discussed.

Key words: cholesteatoma, hearing loss, deafness, tympanoplasty, ossicles

Address for correspondence and reprint requests: Dr Roslenda bt Abdul Rahman, Department of ORL Head & Neck Surgery, Universiti Kebangsaan Malaysia Medical Centre, Jalan Yaacob Latif, Bandar Tun Razak, 56000 Cheras, Kuala Lumpur. Tel:+603 9145 6576. Fax: +603 9145 7765. Email: lenda_orl@yahoo.com

INTRODUCTION

Only 2-4% of cholesteatomas presenting to paediatric otologist are congenital in origin. Disease severity can range from intratympanic pearls to middle ear and mastoid obliteration (Richter & Lee 2009). Derlacki & Clemis (1965) in their article established the clinical criteria for the diagnosis of congenital cholesteatoma (CC). These include a pearly white mass medial to an intact tympanic membrane, a normal pars tensa and flaccida, and no previous history of otorrhoea or perforation, or previous otologic procedure. Levenson et al. (1986) revised the criteria by adding that previous bouts of otitis media or effusion should not be the exclusion criteria. However, disease severity depends on location, patients' age, ossicular integrity, and number of anatomic sites involved. These variables have inspired the development of staging systems whereby appropriate surgical approaches can be designed. Computed tomography is necessary and continue to be the best radiographic tool for surgical planning. Over 30% of CC can be extirpated through a transcanal approach. Involvement of the posterior quadrant, over three anatomic subsites, or the mastoid cavity obligates standard canal wall up techniques. Canal wall down procedures are rarely required (Richter & Lee 2009). As demonstrated in our case, the clinical presentation of CC may not be typical as that suggested by the criteria mentioned.

CASE REPORT

A 6-year-old boy presented to our clinic with left ear discomfort for one year with mild reduction hearing of the ipsilateral ear. He also had recurrent episodes of left sided otorrhoea two months prior to presentation. There was copious foul smelling blood stained discharge which partially resolved with ear drops. There

was no vertigo, tinnitus or facial asymmetry. An otoscopic examination of the left ear revealed an intact, dull tympanic membrane and a whitish mass in the middle ear. There was posterior ear canal wall sagging with keratin debris. The tuning fork test revealed a conductive hearing loss on the left. Pure tone audiogram showed moderate conductive hearing loss with an air bone gap of 40dB on the left and normal hearing on the right. Tympanometry type B was found on the left and normal on the right. High resolution computed tomography (HRCT) of the temporal bone was performed and showed evidence of extensive cholesteatoma with erosion of the scutum and ossicles (Figure 1).

He was subjected to elective mastoid exploration and intraoperatively, there was a large attic perforation seen with overlying keratin debris. The pars tensa was intact while the postero-superior wall of the external auditory canal was eroded. The mastoid, mesotympanum and epitympanum were filled with granulation tissue. The ossicles including the stapes footplate were eroded and the body of the incus was enveloped by granulation tissue. The tegmen tympani, round window and oval window were intact. There was dehiscence of the facial canal along the tympanic segment. The vertical, tympanic and labyrinthine segments of the facial canal were intact and preserved. In view of the extensiveness of the disease, he underwent radical mastoidectomy and tympanoplasty type V. Postoperatively, the patient was continued on intravenous rocephin and mastoid bandage for 2 days. Ribbon gauze soaked with BIPP packing was inserted and kept for 2 weeks.

At the time of writing, the patient remains well and has no more ear discharge. The left mastoid cavity was well epithelized and the neo-tympanic membrane was intact.

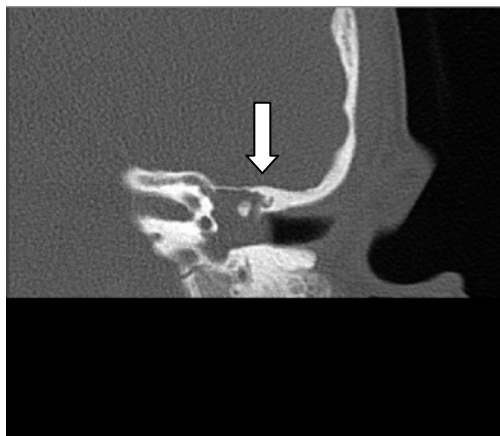


Figure 1: High resolution CT of temporal bone showed evidence of cholesteatoma with erosion of scutum and ossicles (arrow)

DISCUSSION

It is well accepted that CC behave in a more aggressive manner than the acquired form. The most common presenting complaint is hearing reduction (Darrouzet et al. 2002; Nelson et al 2002). As the disease progress a patient may present with vertigo, facial nerve palsy or intracranial abscess (Darrouzet et al. 2002). Early diagnosis decreases the size of CC and subsequently decreases the incidence of complications. Early detection is possible via routine audiological or otological screening.

There are several theories on the pathophysiology of congenital cholesteatoma of the middle ear include presence of congenital cell rest, metaplasia of middle ear epithelium, and papillary ingrowth through an intact tympanic membrane (Bennett et al. 2006). Research reports depict that the most common location are anterior superior quadrant followed by posterior superior quadrant of the tympanic membrane (Darrouzet et al. 2002; Koltai et al. 2002; Bennet et al. 2006; Nelson et al. 2002). It is believed that these cholesteatomas behave in a more aggressive manner than the acquired form. This is based on frequent findings

of more extensive invasion in a normally pneumatized temporal bone with ossicular and labyrinthine involvement at initial surgery (Darrouzet et al. 2002).

Koltai et al. (2002) reported that most cholesteatoma start out as a matrix enclosed spherical keratin pearl in the anterior superior quadrant. Accordingly, the pearl then grows like a round inflated balloon. Anterior growth is towards the eustachian tube, inferiorly towards the hypotympanum and posteriorly towards the handle of the malleus. Posterior growth may extend further, involving the incudostapedial joint and the stapes suprastructure, as well as up towards the incudomalleolar joint, around the incus, and into the attic. The growth of CCs may progress from the attic into the antrum and then into the mastoid and follows the pattern of the enlargement of other categories of middle ear cholesteatomas. As there have been no case reports of CCs involving the otic capsule, Koltai et al. (2002) concluded that a young child with otorrhoea, conductive hearing loss and tympanic membrane perforation at a nontraditional location with cholesteatoma filling the mastoid cavity, like in this patient, may represent the end point in the natural history of CC. This observation supports the notion that this case should be classified as CC. In addition, the staging system proposed by Potsic et al. (2002) (Table 1) and Nelson et al. (2002) (Table 2) would categorise this case as the last stage, namely stage 4 and type 3 respectively. In the staging system proposed by Potsic et al. (2002) extension. On the other hand, type 3 in Nelson's classification refers to CCs in mesotympanum with mastoid extension as well.

The age of this patient at presentation favours CC even though the lesion was outside the accepted definition. Findings from large series revealed that the occurrence of CC is among younger children (mean age 5.6 years) (McGill et al. 1991;

Table 1: Staging sytem by Potsic *et al* (adapted from Bennett et al. 2006)

| | |
|------------------|---|
| Stage I | Single quadrant, no ossicular involvement or mastoid involvement |
| Stage II | Multiple quadrants, no ossicular involvement or mastoid involvement |
| Stage III | Ossicular involvement; no mastoid involvement |
| Stage IV | Mastoid extension (regardless of findings elsewhere) |

Table 2: Staging system by Nelson *et al* (adapted from Bennett et al. 2006)

| | |
|---------------|---|
| Type I | Mesotympanum with no incus or stapes erosion |
| Type 2 | Mesotympanum or attic with ossicular erosion but no mastoid extension |
| Type 3 | Mesotympanum with mastoid extension |

Rizer & Luxford 1998) compared to acquired cholesteatoma (mean 9.7 years) (Koltai et al. 2002). The presence of tympanic membrane perforation in this patient does not exclude the diagnosis of CC as this may still occur with sufficient growth of CC. This is supported by the cases reported by Koltai et al. (2002) who found that CC occurs in young children (ages 3-6 years) presenting with sudden unrelenting otorrhoea, with little or no history of otitis media.

High resolution computed tomography (HRCT) of the temporal bone of these patients generally shows complete occupation of the mastoid by soft tissue that causes osteolysis of the mastoid septa. At exploration, tympanic membrane perforation has been observed at various points in the drum other than the pars flaccida or the posterior quadrant. Accordingly, during mastoidectomy, the entire mastoid, from antrum to tip, is host to the cholesteatoma. The presence of tympanic membrane perforation in an exten-

sive CC suggests 2 possible mechanisms. One is that the volume of cholesteatoma exceeds the capacity of the middle ear and mastoid, resulting in tympanic membrane perforation. The other is that tympanic membrane perforation and subsequent infection accelerate the growth of the CC, resulting in complete filling of the middle ear and mastoid. Acquired cholesteatoma can also present with otorrhoea and complete cholesteatoma invasion of the middle ear and mastoid, but tympanic membrane perforation and otorrhoea typically occur well before the entire mastoid is involved (Koltai et al. 2002). In this case report, even though the perforation is at the pars flaccida in the posterior quadrant, it is still possible that the cholesteatoma is congenital in origin. There was no history of a chronic discharging ear or ear surgery in this patient to support that it is acquired.

As mentioned earlier, recently, two staging systems for CC of the middle ear have been suggested. There was a statistically significant association between the stage, hearing outcomes and residual disease. In both staging systems, the more advanced the disease the higher the recurrence rate. This patient falls into stage 4 in Potsic's and type 3 in Nelson's classification. Therefore, this patient will require long term follow up. For the same reason radical mastoidectomy was performed in this patient in order to eradicate the cholesteatoma.

It had been almost two years from the operation and there were still no signs of recurrence seen at the time this manuscript was written.

CONCLUSION

Early detection of CCs is crucial as it may limit the size of retrotympanic cholesteatoma and reduce the possible risks and complications from surgery as well as from the disease itself. A high index of

suspicion in a young child with reduced hearing and an intact tympanic membrane may help in the diagnosis of CCs.

REFERENCES

- Bennet, M., Warren, F., Jackson, G.C., Kaylie, D . 2006. Congenital cholesteatoma: Theories, Facts and 53 Patients. *Otolaryngol Clin N Am*. **39**: 1081-1094.
- Darrouzet, V., Duclos, J.Y., Portmann, D., Bebear, J.P. 2002. Congenital middle ear cholesteatomas in children: Our experience in 34 cases. *Otolaryngol Head Neck Surg*. **126**:34-39.
- Derlacki, E.L., Clemis, J.D. 1965. Congenital cholesteatoma of the middle ear and mastoid. *Ann Otol Rhinol Laryngol*. **74**(3):706-727.
- Koltai, P.J., Nelson, M., Castellon, R.J., Garabedian, E.N., Triglia, J.M., Roman, S., Roger, G. 2002. The natural history of congenital cholesteatoma. *Arch Otolaryngol Head Neck Surg*. **128**:804-809.
- Levenson, M.J., Parisier, S.C., Chute, P., Wenig, S., Jarbe, C. 1986. A review of twenty congenital cholesteatomas of the middle ear in children. *Otolaryngol Head Neck Surg*. **15**:169-174.
- McGill, T.J., Merchant, S., Healy G.B., Friedman E.M. 1991. Congenital cholesteatoma of the middle ear in children: A clinical and histopathological report. *Laryngoscope*. **101**:606-613.
- Nelson, M., Roger, G., Koltai, P.J., Garabedian, E.N., Triglia, J.M., Roman, S., Castellon, R.J., Hammel, J.P. 2002. Congenital cholesteatoma: Classification, management and outcomes. *Arch Otolaryngol Head Neck Surg*. **128**:810-814.
- Potsic, W.P., Korman, S.B., Samadi, D.S., Wetmore, R.F. 2002. Congenital cholesteatoma : 20 years experience at the Children's Hospital of Philadelphia. *Otolaryngol Head Neck Surg*. **126**:409-413.
- Richter, G.T., Lee, K.H. 2009. Contemporary assessment and management of congenital cholesteatoma. *Curr Opin Otolaryngol Head Neck Surg*. **17**(5):339-345.
- Rizer, F.M., Luxford, W.M. The management of congenital cholesteatoma: surgical result of 42 cases. 1998. *Laryngoscope*. **98**:254-256.